



## X-ray examinations and the X-ray image

Types of X-ray examinations

---

---

---

---

---

---

### What will I gain from this video?

You will learn about different types of radiological examinations of the chest and which ones to order to answer your clinical questions.

---

---

---

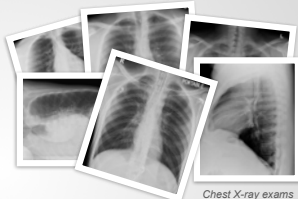---

---

---

### The choices

- The posterior-anterior (PA) X-ray
- The lateral chest X-ray
- The anterior-posterior (AP) X-ray
- The decubitus view
- The lordotic view
- The inspiration/expiration series
- Chest fluoroscopy
- Dual-energy chest X-ray
- Digital tomography (tomosynthesis)



Chest X-ray exams

---

---

---

---

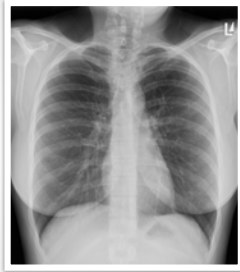
---

---

**The posterior-anterior (PA) X-ray**

Patient must be able:

- To stand or sit upright
- Take a deep breath and hold it
- To understand instructions
- To cooperate



PA X-ray

---

---

---

---

---

---

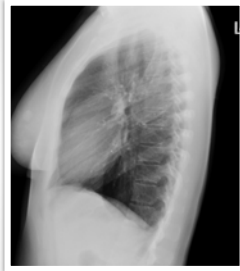---

---

**The lateral (LAT) chest X-ray**

Patient must be able:

- To stand or sit upright
- Take a deep breath and hold it
- To understand instructions
- To cooperate



LAT X-ray

---

---

---

---

---

---

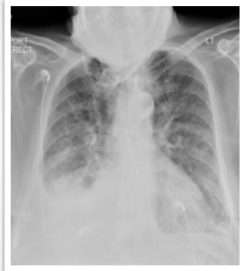---

---

**The anterior-posterior (AP) X-ray**

Critically ill patients

- Patient sitting or supine
- Mobile equipment



AP X-ray

---

---

---

---

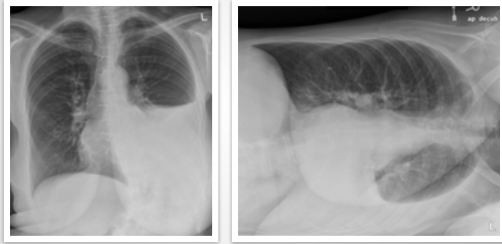
---

---

---

---

### The decubitus view



*Decubitus X-ray*

---

---

---

---

---

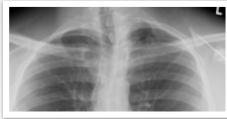
---

---

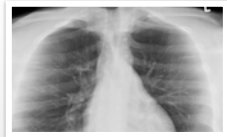
---

### The lordotic view

Eliminate overlap of anatomical structures in the apices



*PA X-ray*



*Lordotic X-ray*

---

---

---

---

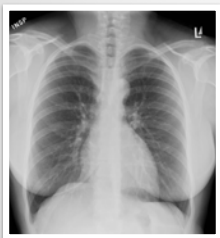---

---

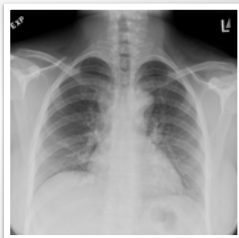---

---

### The inspiration/expiration series



*Inspiration X-ray*



*Expiration X-ray*

---

---

---

---

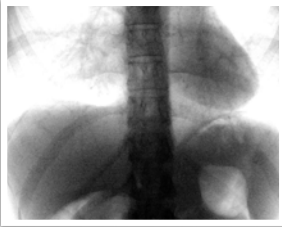---

---

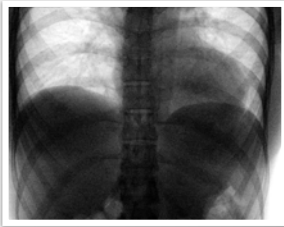
---

---

### Chest fluoroscopy



*Inspiration*



*Expiration*

---

---

---

---

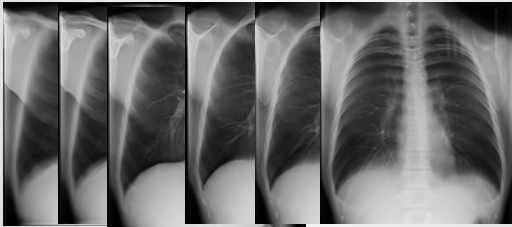
---

---

---

---

### Digital tomography (tomosynthesis)



---

---

---

---

---

---

---

---

The type of chest X-ray examination you order will depend on the specific needs of the patient and clinical indications.

- PA and LATERAL—preferred examination
- AP—for critically ill patients
- Decubitus—pleural effusion
- Lordotic—apices
- Expiration—pneumothorax

---

---

---

---

---

---

---

---